



www.sciencedirect.com
www.rbmonline.com



ARTICLE

Hysteroscopic outpatient metroplasty to expand dysmorphic uteri (HOME-DU technique): a pilot study


A Di Spiezio Sardo ^{a,*}, P Florio ^{b,c}, G Nazzaro ^a, M Spinelli ^a, D Paladini ^a,
C Di Carlo ^a, C Nappi ^a

^a Department of Gynecology and Obstetrics, University of Naples 'Federico II', Italy; ^b Department of Molecular and Developmental Medicine, Section of Obstetrics and Gynecology, University of Siena, Siena, Italy; ^c U.O.C. Obstetrics and Gynecology, 'San Jacopo' Hospital, Pistoia, Italy

* Corresponding author. E-mail address: cdispie@tin.it; attiliodispiezio@libero.it (A Di Spiezio Sardo).



Dr Attilio Di Spiezio Sardo obtained his Medical Degree in 2000, Certification in Obstetrics and Gynaecology in 2005 and PhD in Human Development, Reproduction and Growth in 2008. He worked at the Teaching Faculty at the Unit of Minimally Invasive Therapy and Endoscopy Training Centre, Royal Free Hospital, in 2003. He is Chief of the Hysteroscopy Unit at the Department of Obstetrics and Gynecology, University of Naples 'Federico II', and lectures in Obstetrics and Gynaecology. He has authored over 100 peer-reviewed papers.

Abstract The new classification system of uterine anomalies from the European Society of Human Reproduction and Embryology and the European Society for Gynaecological Endoscopy defines T-shaped and tubular-shaped infantilis uteri as 'dysmorphic'. Such malformations have been proven to be associated with poor reproductive performance. A prospective observational study was conducted with 30 infertile women with dysmorphic uterus who underwent the novel Hysteroscopic Outpatient Metroplasty to Expand Dysmorphic Uteri (HOME-DU) technique. Incisions are made on the uterine walls with a 5 Fr bipolar electrode. The procedure was conducted in outpatients under conscious sedation, using a 5-mm office hysteroscope. The technique was successful in all cases without complications. A net increase of uterine volume was found, as measured at hysteroscopy and three-dimensional transvaginal ultrasound ($P < 0.001$). Uterine morphology improved in all patients but one. At mean follow-up of 15 months, clinical pregnancy rate was 57% and term delivery rate 65%. These early data support HOME-DU as safe and effective in expanding the volume and normalizing the appearance of the uterine cavity of dysmorphic uteri. Although the cohort was small, pregnancy and live births outcomes were favourable in this poor-prognosis group, implying desirable benefits, which should be compared with other techniques. 

© 2014 Reproductive Healthcare Ltd. Published by Elsevier Ltd. All rights reserved.

KEYWORDS: dysmorphic uterus, office hysteroscopy, three-dimensional transvaginal ultrasound, uterine malformation, uterine volume

<http://dx.doi.org/10.1016/j.rbmo.2014.10.016>

1472-6483/© 2014 Reproductive Healthcare Ltd. Published by Elsevier Ltd. All rights reserved.

Introduction

Although the quality of the embryo and transportation to the uterine cavity are obvious requirements for successful implantation, attention has recently focused on the anatomical integrity of the uterine cavity, as a prerequisite for a receptive endometrium (Lin et al., 2002; Rackow and Arici, 2007; Revel, 2012; Saravelos et al., 2008). Indeed, the clinical relevance of congenital anomalies of the uterus in causing infertility and pregnancy loss is undeniable, as they are known to interfere with normal implantation and placentation (Lin et al., 2002; Penzias, 2012; Rackow and Arici, 2007; Revel, 2012; Saravelos et al., 2008). The new classification system of uterine anomalies developed by the European Society of Human Reproduction and Embryology and the European Society for Gynaecological Endoscopy working group of experts (Congenital Uterine Anomalies group) was based on clinical approaches, intending to be as simple as possible (Grimbizis et al., 2013). In this new classification system, Class I incorporates all cases having an uterus with normal outline but with an abnormal lateral wall shape of the uterine cavity (i.e. T-shaped uterus and tubular-shaped/infantilis uteri). These anomalies in the previous American Fertility Society classification, were conversely included in class VII and were mainly related to diethylstilbestrol-related (DES) exposure (American Fertility Society, 1988). Nevertheless, these uterine malformations may also be primary or can be acquired from marginal adhesions with a T-shaped appearance (American Fertility Society, 1988; Grimbizis et al., 2013): the Greek term 'dysmorphia' is used to describe the cavity with such an abnormal morphology (Figure 1).

Several independent studies have shown poor reproductive performance when this kind of uterine malformation is untreated (Berger and Goldstein, 1980; Herbst et al., 1981), as altered volume and shape of the uterine cavity are likely to contribute to defective endometrial receptivity (Revel, 2012). The development of operative hysteroscopy has allowed the treatment of these malformations, using monopolar or bipolar instruments, thus avoiding laparotomy and resulting in lower morbidity (Fernandez et al., 2011; Garbin et al., 1998; Herbst et al., 1981; Katz et al., 1996; Nagel and Malo, 1993).

Class U1/dysmorphic uterus




Figure 1 Dysmorphic uteri according to European Society of Human Reproduction and Embryology and the European Society for Gynaecological Endoscopy classification of female genital tract congenital anomalies (Grimbizis et al., 2013). (a) T-shaped uterus; (b) uterus infantilis.

In this prospective study, surgical outcomes, efficacy and safety are reported of a novel outpatient hysteroscopic technique for expanding the volume and normalizing the morphology of the uterine cavity of dysmorphic uteri (Hysteroscopic Outpatient Metroplasty to Expand Dysmorphic Uteri, [HOME-DU] technique), and on the possibility of improving the reproductive outcomes by mean of the HOME-DU technique.

Materials and methods

Between June 2011 and March 2012, a prospective observational study (Canadian Task Force classification III) was conducted among infertile patients undergoing office hysteroscopy in the Hysteroscopy Unit of the Department of Gynecology and Obstetrics of University of Naples 'Federico II', Italy. Hysteroscopic examinations were carried out immediately after the menstrual phase (day 6–10), as calculated on the basis of the last menstrual period reported by the patients. The study was conducted according to the Declaration of Helsinki (1975) and Good Clinical Practice guidelines. The protocol did not require approval from the University of Naples Ethics committee owing to the observational nature of the study. Before enrolment, the purpose of the study was explained clearly, and all patients received detailed information about the study and the surgical procedure, to which they gave their consent.

Only those patients with a 'dysmorphic' uterus (T-shaped or tubular shaped/infantilis uterus) and at least one of the following were included in the study: history of primary infertility after exclusion of other infertility factors (i.e. patients with long-standing unexplained infertility, patients who had undergone unsuccessful assisted-medical procreation, including both intrauterine insemination and IVF failure, history of repeated early miscarriages [>2] or severe preterm delivery [<25 weeks]). Exclusion criteria were body mass index greater than 30 kg/m^2 ; pregnancy (positive beta-HCG test); previous pregnancy carried to term; utero-vaginal prolapse and severe urinary symptoms; malignancy; other severe intercurrent conditions (coagulative disorders, systemic disease and severe cardiac disease), alone or in combination with any of the above conditions.

The enrolment process is presented in Figure 2.

Pre-surgical assessment of uterine cavity

An evaluation of the volume and morphology of the uterine cavity was carried out by using both office hysteroscopy and three-dimensional transvaginal ultrasound (3D-TVS) assessment.

At hysteroscopy, the uterus was considered to be dysmorphic if it presented with an enlarged distance between the tubal ostia; with a correlation of two-thirds uterine corpus and one-third cervix (T-shaped uterus) and; inverse correlation of one-third uterine body and two-thirds cervix (tubular shaped [infantilis uterus]) (Grimbizis et al., 2013). Interstitial distance (i.e. distance between the two tubal ostia) as well as the transverse diameter at the level of isthmus, were also assessed using the opening of the jaws of the 5 French (5 Fr) grasping forceps (6 mm) as reference measure.

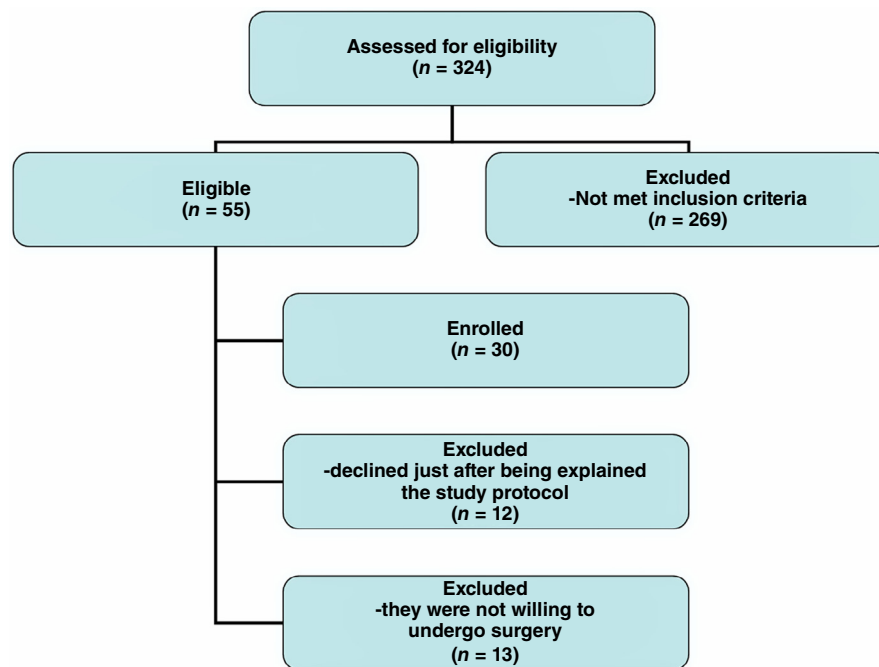





Figure 2 The enrollment process.

After office hysteroscopic assessment dimensional transvaginal sonography (3D-TVS) examinations were carried out by two expert operators (DP and GN) during the luteal phase of the cycle (day 21 to 25): this is considered the optimal time to examine patients for the presence of uterine anomalies, because the endometrium appears thick and echogenic, and the uterine cavity can be clearly differentiated from the surrounding myometrium. A 7.5-MHz probe was used to carry out 3D-TVS. The uterus was visualized in the longitudinal plane, and three-dimensional volume was acquired using the automatic sweep of the mechanical transducer. Uterine volume was analysed online using the technique of planar reformat sections. This technique makes it possible to obtain a coronal view of the uterus, which usually lies perpendicular to the ultrasound beam. Analysis of uterine architecture was carried out in a standardized plane using the interstitial portions of the fallopian tubes as reference points. The distance between tubal ostia (IO), the transversal diameter at the isthmus (I), the I/IO ratio as well as the thickness of the uterine side walls and the depth of the healthy myometrium up to the serosa were also measured (Figure 3).

HOME-DU technique

The HOME-DU technique was carried out immediately after the menstrual phase of the menstrual cycle (day 6–10), under conscious sedation (as achieved by administering midazolam 10 mg and fentanyl 100 µg intravenously), using the vaginoscopic approach, a 5-mm diameter continuous-flow hysteroscope with oval profile and a 30° fore-oblique telescope and a 5 Fr operating channel (Office Continuous Flow Operative Hysteroscopy 'size 5'; Karl Storz, Tuttlingen, Germany). Saline solution was used as distension medium (NaCl 0.9%), which was provided through an electronic system of

Possible section in the width 
 Interstitial distance 
 Isthmic diameter 

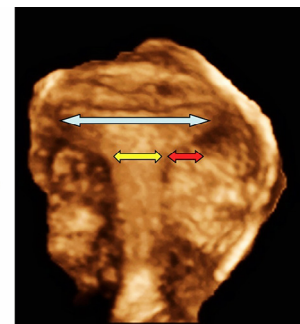


Figure 3 Three-dimensional transvaginal ultrasound imaging referring to the landmarks of the HOME-DU technique: the distance between tubal ostia (IO, interstitial distance); the transversal diameter at the isthmus (I, isthmic diameter), as well as the depth of the healthy myometrium up to the serosa (of which sections are allowed). HOME-DU = Hysteroscopic Outpatient Metroplasty to Expand Dysmorphic Uteri.

irrigation and aspiration (Endomat; Karl Storz, Tuttlingen, Germany). A stable intrauterine pressure of about 40 mmHg was obtained by setting the flow rate on 220–350 mmHg, the negative pressure suction on 0.2 bar and the pressure of irrigation at 100 mmHg.

All procedures were carried out by an expert surgeon (ADSS). The HOME-DU technique (Supplementary Video S1 and Figure 4) consisted of making, first, two incisions with a 5 Fr bipolar Twizzle electrode (Versapoint bipolar Twizzle electrode, Gynecare, Ethicon) on the fibro-muscular constriction rings in the isthmic area of the uterine side walls. Then, other incisions were carefully carried out on the anterior and posterior uterine walls from the fundus up to the isthmus. The depth of all incisions did not exceed 5–6 mm.

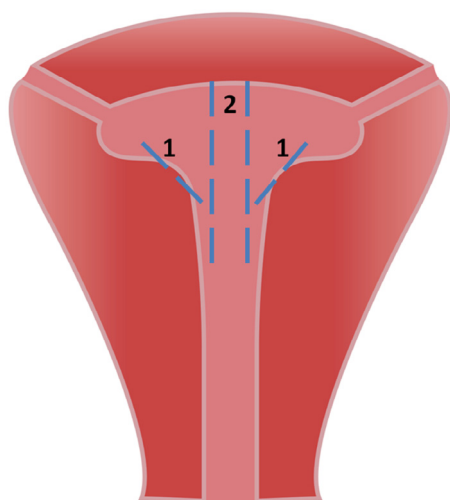


Figure 4 The HOME-DU technique on a frontal view of a T-shaped uterus. (1) incisions on the fibro-muscular constriction rings in the isthmus area of the uterine side walls; (2) incisions on the anterior walls. Note that incisions on posterior wall are symmetric peculiar to anterior incisions. Home-DU = Hysteroscopic Outpatient Metroplasty to Expand Dysmorphic Uteri.

The mildest vapour cutting mode (VC3) with a power of 50 W was set on the electrosurgical generator (Versapoint II; Gynecare, Ethicon). A polyethylene oxide-sodium carboxymethylcellulose gel (Intercoat Gel, Gynecare, Ethicon) to prevent intrauterine adhesions was then applied into the uterine cavity through the inflow channel of the hysteroscope as described elsewhere (Protopapas et al., 1998).

The HOME-DU procedure was considered successfully completed as soon as the gel was applied throughout the uterine cavity and the endocervical canal. All procedures were recorded and their duration was calculated starting from the introduction of the hysteroscope in the uterine cavity until its definitive extraction after the intrauterine application of gel.

Post-surgical evaluation of uterine cavity volume and morphology

Post-surgical evaluation was conducted by office hysteroscopy and 3D-TVS. Office hysteroscopy was carried out in the early proliferative phase of the following menstrual cycle. Neither analgesia nor anaesthesia was administered. The volume and morphology of the uterine cavity were subjectively evaluated as previously described using the opening of the jaws of the 5 Fr grasping forceps as a reference measure. When post-surgical intrauterine synechiae were detected, they were annotated and cut by 5 Fr sharp scissors.

During the luteal phase of the menstrual cycle 3D-TVS was carried out. A three-dimensional volume was acquired using the automatic sweep of the mechanical transducer. The volumes were then compared with those obtained at enrolment, the IO and I diameters were also measured and, compared with those depicted before surgery.

The main parameter evaluated was the increase in the volume of uterine cavity as measured by 3D-TVS. Secondary

parameters were I/IO ratio as evaluated by 3D-TVS; the subjective evaluation of the increased volume of uterine cavity at hysteroscopy; and the presence of intrauterine adhesions.

Follow-up for evaluating the reproductive outcome

The reproductive outcomes were evaluated prospectively. Clinical pregnancy rate was defined as a pregnancy diagnosed by ultrasonographic visualization of one or more gestational sacs or definitive clinical signs of pregnancy; live birth rate was defined as a delivery of a live fetus after 20 completed weeks of gestational age that resulted in at least one live baby born; spontaneous abortion rate was defined as the spontaneous loss of a clinical pregnancy before 20 completed weeks of gestation; term delivery rate, defined as delivery of a live baby born after 37 weeks of gestation. Reproductive histories were obtained by telephone interview from all women who had undergone the HOME-DU technique tri-monthly.

Statistical analysis

All data were analysed with Prism software (GraphPad Software Inc., San Diego, California, USA), and were expressed as mean \pm SD. The Shapiro-Wilks assessment was used to evaluate whether values had a Gaussian distribution, in order to choose between parametric and non-parametric statistical tests. To compare data before and after treatment, the Student's t-test for paired data was used for comparing parametric data, whereas the Wilcoxon test was used for comparing non-parametric data, respectively. Statistical significance was set at $P < 0.05$.

Results

The main characteristics of patients enrolled in the study at baseline are presented in Table 1. In particular, of the 30 women evaluated at enrolment, none had either malformation attributable to DES exposure, or an acquired T-shaped malformation. The median age of the patients was 32 ± 3.1 years, and all were white. The mean volume of uterine cavity, as measured by 3D-TVS was 1.4 ± 0.2 cm³, with a I/IO ratio of 0.35 ± 0.07 for T-shaped uteri and of 0.67 ± 0.11 for tubular-shaped (infantilis uteri) (Table 1).

Anatomical results

In all cases, the HOME-DU technique was successfully carried out without any significant complication, with a mean duration of the procedure of 8.3 ± 3.1 min.

At follow-up, the volume of the uterine cavity at 3D-TVS was significantly increased after surgery (1.4 ± 0.2 versus 2.1 ± 0.4 cm³; $P < 0.001$) (Figure 5). A significant increase of the I/IO ratio for T-shaped uteri (0.35 ± 0.07 vs 0.62 ± 0.05 ; $P = 0.002$) (Table 1 and Figure 6) and, a significant I/IO ratio

Table 1 Main characteristics of enrolled patients.

Age (years) (mean \pm SD)	32 \pm 3.1
Body Mass Index	24.6 \pm 2.8
History of diethylstilbestrol exposure <i>n</i> (%)	0/30 (0)
Indications for surgery <i>n</i> (%)	
Primary infertility	22 (73)
Repeated spontaneous abortions (>2)	7 (23)
Preterm delivery	1 (3)
Subtypes of 'dysmorphic uteri' <i>n</i> (%)	
T-shaped uterus <i>n</i>	12/30 (40)
Tubular-shaped (infantilis uterus) <i>n</i>	18/30 (60)
Uterine volume at enrolment (cm ³)	1.4 \pm 0.2
I/O ratio at enrolment	
T-shaped uterus	0.35 \pm 0.07
Tubular-shaped uterus	0.67 \pm 0.1
I/O ratio after HOME-DU surgery	
T-shaped uterus	0.62 \pm 0.05 ^a
Tubular-shaped uterus	0.55 \pm 0.11 ^b

^a*P* = 0.002 versus I/O ratio at enrolment.

^b*P* = 0.007 versus I/O ratio at enrolment.

I = transverse diameter at the level of Isthmus; IO = interstitial distance.

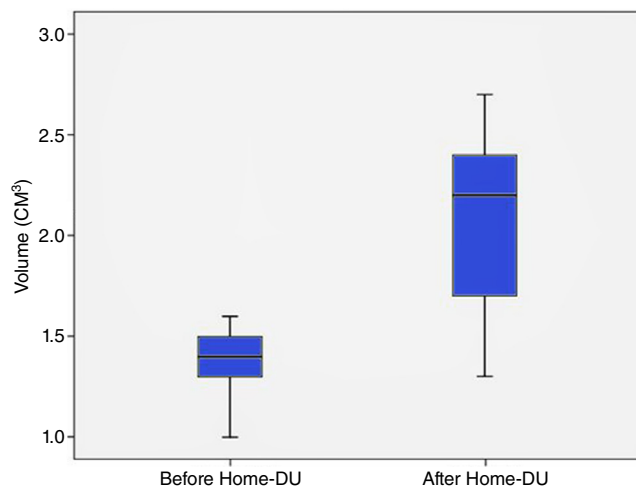


Figure 5 Data on the volume of the uterine cavity measured at three-dimensional transvaginal ultrasound before and after the HOME-DU technique. Uterine volumes before and after surgery were significantly different (*P* < 0.001). HOME-DU = Hysteroscopic Outpatient Metroplasty to Expand Dysmorphic Uteri.

decrease (0.67 \pm 0.1 versus 0.55 \pm 0.11; *P* = 0.007) in the case of tubular-shaped uterus (Table 1 and Figure 7) were observed.

The postoperative results of hysteroscopic examinations were good in most cases, as an increase of uterine cavity volume was noted in all patients, with amelioration in the morphology of the uterus in all women, with the exception of one out of 30 (3%) patients, in whom uterine cavity continued to have a tubular shape.

Mild intrauterine adhesences were detected in the isthmic area only in five patients out of 30 (16.7%) and easily cut with 5 Fr sharp scissors.

Functional results

The mean follow-up period of the 30 patients to evaluate the reproductive outcome was 15 months (range 3–26 months). Seventeen women become pregnant after metroplasty. The reproductive outcomes for their pregnancies are shown in Tables 2 and 3.

The mean time after the first conception was 9 months (range 2–16 months). Overall, the clinical pregnancy rate was 57% after metroplasty (*n* = 17) with a term-delivery rate of 65% (*n* = 11) and a live birth rate of 71% (*n* = 12). Of these 12 deliveries, 58% (*n* = 7) were by caesarean section.

Among patients with primary infertility, a clinical pregnancy rate of 55% (*n* = 12/22) was obtained, with a term-delivery rate of 75% (*n* = 9/22). Of the three postoperative spontaneous abortions, two occurred after IVF.

Among patients with early repeated spontaneous abortions, a clinical pregnancy rate of 71% (*n* = 5/7) was obtained with term delivery rate and live birth rate increased from 0% to 40% (*n* = 2/5) and 60% (*n* = 3/5), respectively. The only preterm delivery was due to a premature membrane rupture at 36 weeks of gestation.

Only one patient with a history of pre-term delivery (<25 weeks) and T-shaped uterus was enrolled, and she has not yet become pregnant.

No cases of cervical incompetence or uterine ruptures were reported in our series after surgery.

Discussion

In the present study, the improvement of uterine morphology in the case of T-shaped and tubular-shaped uteri, obtained through a new surgical outpatient hysteroscopic technique, named HOME-DU technique. It consists of making several incisions through miniaturized bipolar electrodes first on the constriction fibromuscular rings around the isthmus area of the uterine side walls and then on the anterior and posterior walls. Indeed, by obtaining a normally shaped and sized cavity, weakening of the uterine walls was avoided. The efficacy of the HOME-DU technique was thus confirmed by postoperative diagnostic hysteroscopy and 3D-TVS that showed that hysteroscopic metroplasty produced good anatomical results, expanding the volume and improving morphology of the uterine cavity of dysmorphic uteri.

T-shaped and tubular-shaped (infantilis uteri) are rare Müllerian anomalies characterized by a normal outline but with an abnormal lateral wall's shape of the uterine cavity: T-shaped uterus is characterized by a correlation of two-thirds uterine corpus and one-third cervix and uterus infantilis by an inverse correlation of one-third uterine body and two-thirds cervix (Grimbizis et al., 2013). The clinical relevance of these Müllerian anomalies relies on the fact that infertility and obstetric complications are believed to be more common in women with uterine dysmorphism than in those with a normal uterine cavity; however, surgery for a septate uterus have frequently been reported (Homer et al., 2000) but data on minimally invasive surgical treatment of T-shaped and tubular-shaped/infantilis uteri are scarce (Fernandez et al., 2000, 2011; Garbin et al., 1998; Katz et al., 1996; Nagel and Malo, 1993); and, finally, these malformations are

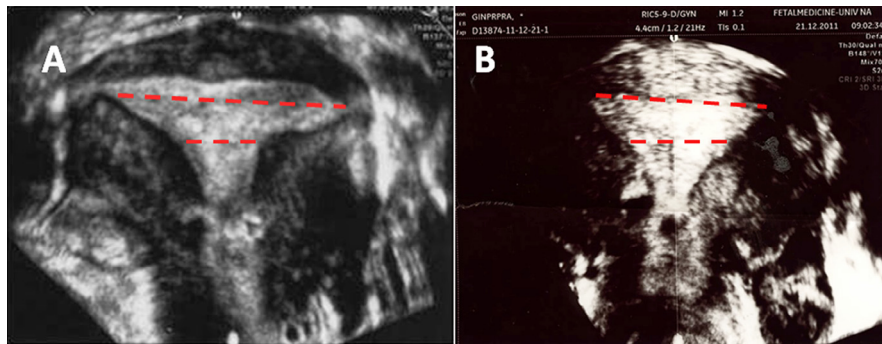


Figure 6 Three-dimensional transvaginal sonography showing an improvement of the volume and morphology of T-shaped uteri before (A) and after (B) the HOME-DU technique. An increase of the I/IO ratio was detected. I = isthmic diameter; IO = interstitial distance.

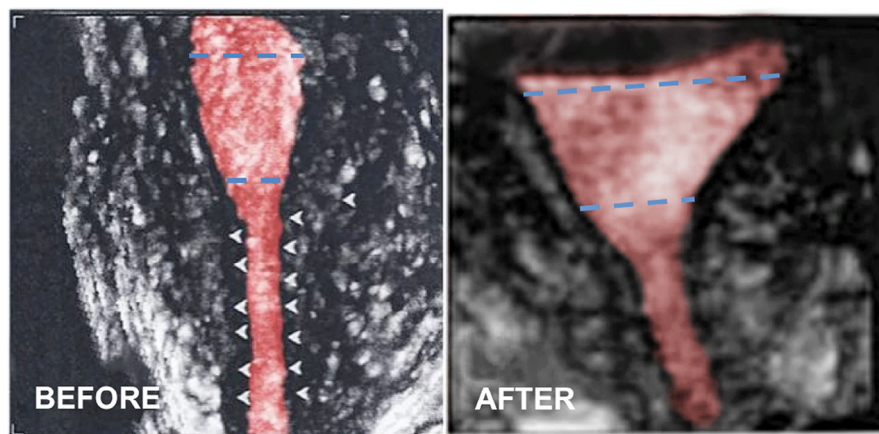


Figure 7 Three-dimensional transvaginal ultrasound showing the improvement of the volume and morphology of tubular-shaped uteri before and after the HOME-DU technique. A significant I/IO ratio decrease was noted. HOME-DU = Hysteroscopic Outpatient Metroplasty to Expand Dysmorphic Uteri; I = isthmic diameter; IO = interstitial distance.

Table 2 Postoperative reproductive outcomes.

<i>Inclusion criteria</i>	<i>Clinical pregnancy rate</i>	<i>Spontaneous abortion rate</i>	<i>Term delivery rate</i>	<i>Live birth rate</i>
Primary infertility (n = 22)	12/22 (55%)	3/12 (25%)	9/12 (75%)	9/12 (75%)
Repeated early spontaneous abortions (≥ 2) (n = 7)	5/7 (71%)	2/5 (40%)	2/5 (40%)	3/5 (60%)
Preterm delivery (n = 1)	0/1 (0.0%)	–	–	–
Total (n = 30)	17/30 (57%)	5/17 (29%)	11/17 ^a (65%)	12/17 (71%)

The dashes denotes 0.

^aOnly one case of preterm delivery (6%).

encountered in young infertile patients with no history of DES exposure and despite the fact that use of DES in pregnancy was prohibited about 40 years ago.

In the present study, a novel outpatient hysteroscopic technique is first reported: the HOME-DU technique for plastic enlargement of dysmorphic uteri, which resembles the surgical principles of the technique first described by Protopapas et al. (1998) in their 'myometrial scoring', by which they were able to enlarge uterine cavity size and improve menstrual function in women affected by Asherman's syndrome. Different

methods and instruments have been used for hysteroscopic metroplasty for T-shaped and tubular-shaped uteri, including scissors and a resectoscope with a monopolar hook (Fernandez et al., 2000, 2011; Garbin et al., 1998; Katz et al., 1996; Nagel and Malo, 1993) or bipolar energy (Homer et al., 2000).

On the contrary, our technique combines the surgical principles of traditional resectoscopic surgery and the use of latest innovations of minimally invasive operative hysteroscopy and bipolar technology. The outstanding change of the shape of

Table 3 Main characteristics of the 17 post-surgical pregnancies.

Patient	Age (years)	Interval between HOME-DU surgery and positive pregnancy test (months)	Abortion (weeks of gestation)	Delivery (weeks of gestation)	Mode of delivery	Indication of caesarean section	Neonatal weight at delivery (g)
1	29	2	7				
2	35	6		40	CS	Personal choice	3300
3	32	9		36	VD		2500
4	33	12	6				
5	33	14		39	CS	Breech presentation	3100
6	30	13		40	VD		3400
7	35	6		38	VD		3200
8	30	16	8				
9	34	11		40	CS	Failure to progress	4010
10	32	10		39	VD		3700
11	32	9		41	CS	Personal choice	3540
12	29	13	10				
13	26	6		37	VD		3020
14	36	9		40	CS	Failure to progress	3690
15	30	5		39	CS	Personal choice	2890
16	34	6	9				
17	32	10		39	CS	Personal choice	2960

CS = caesarean section; VD = vaginal delivery.

the uterine cavity may result form an extensive remodelling of uterus stimulated by the incisions on the excess of fibro-muscular tissue on the lateral uterine walls, but also by those performed on the anterior and posterior uterine walls from the fundus up to the hystmus. The procedure is carried out in the office setting under conscious sedation (as the depth of the incisions is likely to cause a stimulation of the nerve fibres within the myometrium), and using a small diameter hysteroscope with a working channel through which miniaturized instruments are inserted within the uterine cavity. The use of this approach avoids cervical dilatation, which may be particularly challenging in such dysmorphic uteri (i.e. narrow cavity, longer cervical canal), thus reducing the risk of complications (Bradley, 2002). In addition, the putative injury caused by cervical dilators on uterine walls may make more difficult the identification of the bulging of uterine side walls, where the incisions should be first performed. Finally, avoiding cervical dilatation also decreases the risk of cervical incompetence and of uterine perforation, which are the most common complication. Indeed no cases of cervical incompetence were detected in our series after such surgery and only one patient delivered before 37 weeks of gestation.

Finally, another important result of the present prospective study was the low incidence of post-surgical synechia, probably owing to the use of a polyethylene oxide-sodium carboxy-methylcellulose gel at the end of the procedure, as we have already reported on the efficacy of such a gel in reducing postsurgical adhesions (Di Spiezio Sardo et al., 2011).

In the present study, we also observed that improvement of morphology and volume of the uterine cavity was associated with improvement in reproductive outcomes: neither case of intrauterine nor neonatal death was reported in our series and only one patient delivered prematurely (36 weeks) owing to membrane rupture.

Our results are substantially in accordance with previous reports (Fernandez et al., 2011; Garbin et al., 1998; Giacomucci et al., 2011; Katz et al., 1996; Nagel and Malo, 1993) despite some differences. For example, both types of dysmorphic uterus (i.e. tubular [infantilis uterus] and T-shaped uterus) were included in our series; inclusion criteria were more strict (i.e. all women with previous term-deliveries were excluded and only severe [<24 weeks] preterm delivery included); none of the 30 women had either malformation attributable to DES exposure or an acquired T-shaped malformation; the mean follow-up time for evaluating reproductive outcome was shorter (15 months versus 20.3 months (Garbin et al., 1998); 39 months (Fernandez et al., 2011)). Particularly, according to our intentions, the choice of excluding patients with secondary infertility reduced biases, which could potentially impair the evaluation of the post-surgical reproductive outcomes.

We believe that dysmorphic uterus (both T-shaped and tubular-shaped [infantilis uteri]) is a major concern in reproduction. Accordingly, we combined three different groups of patients in whom the presence of such a malformation was the only common trait that could explain the uneventful reproductive outcome. Our results do support the notion, in disagreement with other investigators (Katz et al., 1996; Nagel and Malo, 1993), that surgical correction of Müllerian anomalies could induce a uterine remodelling involving not only macroscopic (i.e. morphology and vascularization), but also microscopic (i.e. endometrial receptivity) changes. Recent data have pointed to the role of mechanical endometrial injury induced by biopsy and scratch or hysteroscopy to improve implantation in women with unexplained recurrent implantation failure (Potdar et al., 2012), probably throughout different pathways, such as provocation of immunological reaction, subsequent release of cytokines and growth factors, and

increased implantation rate (Barash et al., 2003; Mansour and Aboulghar, 2002; Raziel et al., 2007).

In the light of these findings, what remains to be addressed is whether the reproductive outcomes reported here are attributable to the improvement of the uterine cavity morphology and volume or to other factors (endometrial injury induced by biopsy and scratch or hysteroscopy). Indeed, a limitation of our study was the absence of control groups who had been managed expectantly to compare the two main outcomes of the present study (postoperative uterine volume, morphology improvement and pregnancy rate) against no or minimal (endometrial biopsy and scratch) procedure; different methods and instruments (as in the case of the standard procedure described by Garbin et al., 1998); or relevance of anti-adhesions treatment. Larger multi-centre randomized controlled studies are awaited to explore such clinical questions. In any case, it must be borne in mind that a large number of studies (Berger and Goldstein, 1980; Fernandez et al., 2011; Garbin et al., 1998; Giacomucci et al., 2011; Nagel and Malo, 1993) have already demonstrated a poor reproductive outcome in infertile patients with malformation and clinical characteristic similar to those considered as inclusion criteria in our trial, which do not undergo any surgical intervention. Additional studies, however, are recommended with a larger number of patients of each subgroup the specific role of the HOME-DU technique can be better evaluated in these different scenarios.

We found that the caesarean rate for term pregnancies was high (58%) in our study, in accordance with 53% rate reported by Fernandez et al. (2011). In the present study, the main indication for caesarean delivery in these cases was neither the metroplasty itself nor any other obstetrical indication, but rather the feelings of the mother toward the pregnancy after a personal history of infertility or early spontaneous abortion. Vaginal delivery is possible after metroplasty, but in the light of the research, there should be no hesitation about choosing caesarean as the mode of delivery, as metroplasty is likely to induce uterine fragility. Obstetric management must be careful, although no uterine rupture is reported in the present study and in other international studies (Fernandez et al., 2011; Garbin et al., 1998; Giacomucci et al., 2011; Nagel and Malo, 1993).

In conclusion, congenital uterine malformations of the female genital tract are a challenge for the therapeutic decision-making process, owing to their high prevalence and possible effect on women's reproductive health. Despite a limited cohort of patients, our preliminary findings would support the safety and efficacy of this novel minimally invasive technique for expanding the volume and improving morphology of the uterine cavity of dysmorphic uteri, thus offering new approaches in improving reproductive outcomes, without any significant obstetrical complications, which could be beneficial particularly for infertile patients and patients with history of repeated spontaneous abortions. Further larger controlled studies are needed to confirm such promising results.

Appendix: Supplementary material

Supplementary data to this article can be found online at [doi:10.1016/j.rbmo.2014.10.016](https://doi.org/10.1016/j.rbmo.2014.10.016).

References

- American Fertility Society, 1988. The AFS classification of adnexal adhesions, distal tubal occlusion, tubal occlusion secondary to tubal ligation, tubal pregnancies, Mullerian anomalies and intrauterine adhesions. *Fertil. Steril.* 49, 944–955.
- Barash, A., Dekel, N., Fieldust, S., Segal, I., Schechtman, E., Granot, I., 2003. Local injury to the endometrium doubles the incidence of successful pregnancies in patients undergoing in-vitro fertilization. *Fertil. Steril.* 79, 1317–1322.
- Berger, M.J., Goldstein, D.P., 1980. Impaired reproductive performance in DES-exposed women. *Obstet. Gynecol.* 55, 25–27.
- Bradley, L.D., 2002. Complications in hysteroscopy: prevention, treatment and legal risk. *Curr. Opin. Obstet. Gynecol.* 14, 409–415.
- Di Spiezio Sardo, A., Spinelli, M., Bramante, S., Scognamiglio, M., Greco, E., Guida, M., Cela, V., Nappi, C., 2011. Efficacy of a polyethylene oxide-sodium carboxy-methylcellulose gel in prevention of intrauterine adhesions after hysteroscopic surgery. *J. Minim. Invasive Gynecol.* 18, 462–469.
- Fernandez, H., Gervaise, A., de Tayrac, R., 2000. Operative hysteroscopy for infertility using normal saline solution and a coaxial bipolar electrode: a pilot study. *Hum. Reprod.* 15, 1773–1775.
- Fernandez, H., Garbin, O., Castaigne, V., Gervaise, A., Levaillant, J.M., 2011. Surgical approach to and reproductive outcome after surgical correction of a T-shaped uterus. *Hum. Reprod.* 26, 1730–1734.
- Garbin, O., Ohl, J., Bettahar-Lebugle, K., Dellenbach, P., 1998. Hysteroscopic metroplasty in diethylstilboestrol-exposed and hypoplastic uterus: a report on 24 cases. *Hum. Reprod.* 13, 2751–2755.
- Giacomucci, E., Bellavia, E., Sandri, F., Farina, A., Scagliarini, G., 2011. Term delivery rate after hysteroscopic metroplasty in patients with recurrent spontaneous abortion and T-shaped, arcuate and septate uterus. *Gynecol. Obstet. Invest.* 71, 183–188.
- Grimbizis, G.F., Gordts, S., Di Spiezio Sardo, A., Brucker, S., De Angelis, C., Gergolet, M., Li, T.C., Tanos, V., Brölmann, H., Gianaroli, L., Campo, R., 2013. The ESHRE/ESGE consensus on the classification of female genital tract congenital anomalies. *Hum. Reprod.* 28, 2032–2044.
- Herbst, A.L., Hubby, M.M., Azizi, F., Makii, M.M., 1981. Reproductive and gynecologic surgical experience in diethylstilbestrol-exposed daughters. *Am. J. Obstet. Gynecol.* 141, 1019–1028.
- Homer, H.A., Li, T.C., Cooke, I.D., 2000. The septate uterus: a review of management and reproductive outcome. *Fertil. Steril.* 73, 1–14.
- Katz, Z., Ben-Arie, A., Lurie, S., Manor, M., Insler, V., 1996. Beneficial effect of hysteroscopic metroplasty on the reproductive outcome in a 'T-shaped' uterus. *Gynecol. Obstet. Invest.* 41, 41–43.
- Lin, P.C., Bhatnagar, K.P., Nettleton, G.S., Nakajima, S.T., 2002. Female genital anomalies affecting reproduction. *Fertil. Steril.* 78, 899–915.
- Mansour, R., Aboulghar, M., 2002. Optimizing the embryo transfer technique. *Hum. Reprod.* 17, 1149–1153.
- Nagel, T.C., Malo, J.W., 1993. Hysteroscopic metroplasty in the diethylstilbestrol-exposed uterus and similar nonfusion anomalies: effects on subsequent reproductive performance; a preliminary report. *Fertil. Steril.* 59, 502–506.
- Penzias, A.S., 2012. Recurrent IVF failure: other factors. *Fertil. Steril.* 97, 1033–1038.
- Potdar, N., Gelbaya, T., Nardo, L.G., 2012. Endometrial injury to overcome recurrent embryo implantation failure: a systematic review and meta-analysis. *Reprod. Biomed. Online* 25, 561–571.
- Protopapas, A., Shushan, A., Magos, A., 1998. Myometrial scoring: a new technique for the management of severe Asherman's syndrome. *Fertil. Steril.* 69, 860–864.
- Rackow, B.W., Arici, A., 2007. Reproductive performance of women with Mullerian anomalies. *Curr. Opin. Obstet. Gynecol.* 19, 229–237.

Raziel, A., Schachter, M., Strassburger, D., Bern, O., Ron-El, R., Friedler, S., 2007. Favourable influence of local injury to the endometrium in intracytoplasmic sperm injection patients with high-order implantation failure. *Fertil. Steril.* 87, 198–201.

Revel, A., 2012. Defective endometrial receptivity. *Fertil. Steril.* 97, 1028–1032.

Saravelos, S.H., Cocksedge, K.A., Li, T.-C., 2008. Prevalence and diagnosis of congenital uterine anomalies in women with reproductive failure: a critical appraisal. *Hum. Reprod. Update* 14, 415–419.

Declaration: The authors report no financial or commercial conflicts of interest.

Received 6 March 2014; refereed 25 October 2014; accepted 28 October 2014.