

Clinical evaluation of a viscoelastic gel for reduction of adhesions following gynaecological surgery by laparoscopy in Europe

P.Lundorff¹, J.Donnez², M.Korell³, A.J.M.Audebert⁴, K.Block⁵ and G.S.diZerega^{6,7}

¹Department of Obstetrics and Gynecology, Viborg Hospital, Viborg, Denmark, ²Université Catholique de Louvain, Cliniques Universitaires Saint-Luc, Brussels, Belgium, ³Department of Obstetrics and Gynecology, Klinikum Duisburg, Zuden Rehwiesen 9, Duisburg, Germany, ⁴Institut Greenblatt France, Bordeaux, France, ⁵FzioMed Inc., 231 Bonetti Drive, San Luis Obispo, California, and ⁶Obstetrics and Gynecology, Livingston Reproductive Biology Laboratories, Keck–USC School of Medicine, Los Angeles, California, USA

⁷To whom correspondence should be sent at: University of Southern California Keck School of Medicine, Obstetrics and Gynecology, Livingston Laboratories, 1321 N. Mission Road, Los Angeles, CA 90033, USA. E-mail: GSD1270@aol.com

BACKGROUND: Commonly used adhesion prevention devices either cannot be applied or are difficult to use via laparoscopy. A viscoelastic gel was developed specifically for adhesion prophylaxis during minimally invasive surgery. **METHODS:** Randomized, third party-blinded, parallel-group design conducted at four centres. Patients (18–46 years old) underwent laparoscopic surgery with second look 6–10 weeks later. Viscoelastic gel coated adnexa and adjacent tissues. Blinded reviews of videotapes were quantified by American Fertility Society (AFS) adhesion scores. **RESULTS:** In 25 treatment patients, surgery was performed on 45 adnexa. Coverage of surgical sites at risk for adhesions was typically accomplished with ~15 ml of viscoelastic gel which was delivered in ~90 s. In 24 control patients, surgery alone was performed on 41 adnexa. Treated adnexa showed a decrease in AFS score (11.9–9.1). In contrast, control adnexa showed an increase in AFS score (8.8–15.8). This difference in second-look AFS scores (42% reduction) is significant ($P < 0.01$). Ninety-three per cent of treated adnexa did not have a worse adhesion score in contrast to 56% of control adnexa. Combining scores into prognostic categories also show significant treatment effect of the viscoelastic gel ($P < 0.01$). **CONCLUSION:** Viscoelastic gel was easy to use via laparoscopy and produced significant reduction in adnexal adhesions. It provides benefits to patients undergoing gynaecological surgery.

Key words: adhesions/laparoscopy/Oxiplex/prophylaxis/viscoelastic gel

Introduction

Use of adhesion prevention adjuvants has become the standard of practice following conservative gynaecological surgery (Canis *et al.*, 2001; Tulandi, 2001). The frequent occurrence of adhesions after peritoneal cavity surgery and clinical consequences of adhesions include increased rates of re-operation (Lower *et al.*, 2000), post-operative bowel obstruction (Menzies, 1990), infertility (Marana, 2000) and chronic pelvic pain (Almeida and Val-Gallas, 1997; Howard *et al.*, 2000; Sutton *et al.*, 2000; Onders and Mittendorf, 2003) which markedly increases healthcare costs (Ray *et al.*, 1993), and makes adhesion prevention a major contributor to successful surgical outcome.

Adhesion prevention adjuvants became available to practising gynaecologists in 1990 with the introduction of Interceed Absorbable Adhesion Barrier (Gynecare, USA) (Interceed Adhesion Barrier Study Group, 1989). Other site-specific barriers soon followed, including Preclude

(Gore-Tex, USA) (Surgical Membrane Study Group, 1992) and Seprafilm Bioabsorbable Membrane (Genzyme, USA) (Becker *et al.*, 1996; Diamond, 1996). These first generation adhesion prevention devices were widely used in laparotomy procedures but were found to be a challenge when used via laparoscopy. Although the Food and Drugs Agency (FDA) approved Intergel Adhesion Prevention Solution in 2001 for use via laparotomy (Johns *et al.*, 2001a,b; Lundorff *et al.*, 2001), many gynaecologists found Intergel easy to use via laparoscopy. When Intergel was withdrawn from the market in 2003, the only clinically available instillate in Europe indicated for the reduction of post-operative adhesion formation was Adept (diZerega *et al.*, 2002). Early clinical studies with N,O-carboxymethylchitosan in volumes of ~300 ml showed promising clinical benefit (Diamond *et al.*, 2003). Development of site-specific adhesion prevention devices, which could be easily delivered during laparoscopy, was led by initial clinical studies of SprayGel (Johns *et al.*, 2001a,b;

Mettler *et al.*, 2003). Recently, Oxiplex/SP became available to spinal surgeons for the reduction of pain and weakness due to adhesion formation following laminectomy (Kim *et al.*, 2003). A similar formulation of Oxiplex, viscoelastic gel, was shown in preclinical studies to be most effective in reducing adhesions to peritoneal surfaces following surgery (Berg *et al.*, 2003). This paper reports the results of the first clinical study utilizing viscoelastic gel, a single component adhesion prevention device that can easily be administered to pelvic sites during laparoscopic surgery.

Materials and methods

Oxiplex/AP Gel, a viscoelastic gel composed of polyethylene oxide and carboxymethylcellulose stabilized by calcium chloride, was manufactured by FzioMed, Inc. (San Luis Obispo, USA). Oxiplex/AP Gel is a sterile, non-pyrogenic gel adjusted to isotonicity with sodium chloride.

The study was a randomized, third party blinded, parallel-group design conducted at four centres in Europe. The study plan was approved for human evaluation by the relevant committee at each study centre. Patients were 18–46 years old requiring peritoneal cavity surgery by way of laparoscopy and expected to undergo a second-look laparoscopy as part of their treatment plan 6–10 weeks after the initial surgery. FzioMed, Inc. provided financial assistance to the patients for the second-look laparoscopy if it was not covered by their insurance carrier. Patients with a history of diabetes, hepatic, or renal disorders, or those presenting with pelvic or abdominal infection were excluded from the study. Also excluded from the study were patients with a history of malignancy within 5 years of study initiation. Patients who received systemic corticosteroids within 30 days of the initial surgery or post-operative hydrotubation were excluded. All patients had a negative pregnancy test within 24 h of the scheduled surgery. Patients receiving any adhesion prevention adjuvant such as Interceed, Sefrafilm, SprayGel or Intergel, or those receiving any peritoneal instillate including instillates containing corticosteroids, non-steroidal anti-inflammatory agents or Hyskon, or those in whom any absorbable haemostat was left in the peritoneal cavity were excluded from the study. Patients who were pregnant, including ectopic pregnancy, or those undergoing reversal of previous surgical sterilization did not participate.

At the time of the initial surgical procedure, patients were assigned the next available study number as determined by randomization schedule corresponding to study device or control which was surgery alone. All surgeries were performed with a full pneumoperitoneum. After initiation of the laparoscopic procedure and before any adhesiolysis or other surgery, the investigator evaluated the adnexa including manipulation of the ampulla and ovaries with a probe with inspection of the pelvic sidewall and ovarian fossa. The entire procedure was recorded on videotape. The patient was excluded from randomization if any of the following events occurred during the surgical procedure: no evidence of adnexal disease or endometriosis, bowel perforation, or conversion to laparotomy. At the conclusion of the operation, each patient who met all inclusion and exclusion criteria received either Oxiplex/AP Gel treatment or no additional therapy (control).

Application of Oxiplex/AP Gel

For patients who received Oxiplex/AP Gel, the following procedures were followed. At the end of the surgical procedures, subjects were placed in reverse Trendelenberg position to facilitate collection of residual fluid from the cul-de-sac. Thereafter, residual fluid was

aspirated until <10 ml of fluid remained in the cul-de-sac. A single layer of gel was applied via a 30.5 cm long × 5 mm canula applicator in sufficient volume to completely coat the surgical site with a viscous layer of gel. The surgical sites included anterior and posterior surface of the ovary, Fallopian tube including mesosalpinx, the surfaces between the Fallopian tube and ovary, surface of the ampulla, adjacent pelvic sidewall including the ovarian fossa, and the lateral aspect of the uterus that could come in contact with the adnexa. The amount of gel required to coat the adnexa did not exceed 30 ml. Thereafter, the surgical instruments were removed and the pneumoperitoneum evacuated.

Six to 10 weeks after the initial surgical procedure, a second-look laparoscopic procedure was performed. At that time the adnexa were evaluated in a manner similar to the initial laparoscopic surgical procedure and the image recorded on videotape.

Blinded reviews of the videotapes were performed to quantify adhesion scores by the method of the American Fertility Society (AFS, 1988). AFS adnexal adhesion score is determined by assessing the extent (area of adnexal organ covered by adhesions) and severity (severe: if the adhesion requires cutting to remove or tears peritoneal surfaces when removed bluntly or requires haemostasis; filmy if not severe) of the adhesions involving the Fallopian tube and ovary. Summing the scores for the Fallopian tube and the ovary provided a clinical category for the adhesion score: minimum (0–5), mild (6–10), moderate (11–20), and severe (21–32).

Safety evaluation was based on the patient's post-operative condition and recovery as well as the type and severity of adverse events recorded throughout the study.

Technique for gel application

Like any surgical device, careful attention to the details of application are important for maximal patient benefit. The following procedures for Oxiplex/AP Gel were followed. At the end of the surgical procedures, subjects were placed in reverse Trendelenberg position to facilitate collection of residual fluid from the cul-de-sac. Thereafter, residual fluid was aspirated until <10 ml of fluid remained in the cul-de-sac. A single layer of gel was applied via an applicator in single layers of sufficient volume to completely cover the surgical sites.

Statistical analysis

The treatment and control groups were compared using Student's *t*-test for continuous variables and Fisher's exact test for categorical variables. The number and proportion of sites with adhesions were compared using Student's *t*-test. Adhesion scores were compared using the Wilcoxon rank-sum test and shift tables were analysed by the Cochran–Mantel–Haenszel test with the ridit scores based on the order of adhesion score categories.

Results

A total of 49 female patients, aged 18–46 years, received treatment at four centres. Of the 25 treatment patients, surgery was performed on 45 adnexa followed by coverage of those adnexal sites by Oxiplex/AP Gel. Of the 24 control patients, surgery alone was performed on 41 adnexa. All patients did well following surgery with no unusual post-operative complications. All patients returned for second-look laparoscopy within 6–10 weeks. As a result, efficacy analyses are presented for all 86 adnexa. The type and frequency of the surgical procedures were similar for the two groups. Treatment and control patients underwent

adhesiolysis only (treatment $n = 12$; control $n = 8$ patients) and removal of ovarian endometriosis by cystectomy (treatment $n = 6$; control $n = 3$ patients). Endometriosis involving parietal and visceral peritoneum was present in 33 treatment and 33 control patients. Stage IV endometriosis was treated in six treatment and six control patients. There were no cases of prolonged hospital stay or premature re-admission; there were no reports of prolonged constipation, fevers, or post-operative pain requiring evaluation or hospitalization. No deaths occurred during this study and there were no study discontinuations due to an adverse event.

An Oxiplex Applicator, consisting of 30 cm \times 5 mm cannula, was used to apply a single layer of gel to the adnexa (94 ± 21 s). The amount of gel required to cover the adnexal surfaces with a single layer of gel with the Oxiplex Applicator was found to be ~ 15 ml per adnexa.

Efficacy

As shown in Figure 1, the mean adnexal adhesion score for the Oxiplex/AP Gel-treated adnexa was 11.9 and for the control adnexa 8.8. At the time of second-look laparoscopy, the adnexa that were covered with Oxiplex/AP Gel showed a decrease in mean adnexal adhesion score from 11.9 to 9.1. In contrast, the control adnexa showed an increase in adnexal adhesion score from 8.8 to 15.8. The difference in second-look AFS scores (42% reduction; $P < 0.01$) was statistically significant. The same directional difference in mean adnexal adhesion score was seen for the patient groups without (Figure 2A) and with (Figure 2B) endometriosis. Patients with grade I–III endometriosis showed a reduction in adnexal adhesion score in the Oxiplex/AP Gel-treated group compared to controls (Figure 2C). Whereas Oxiplex/AP Gel worked well to prevent an increase in adhesion score in patients with endometriosis, it did not appear to provide that benefit to patients with grade IV endometriosis (data not shown).

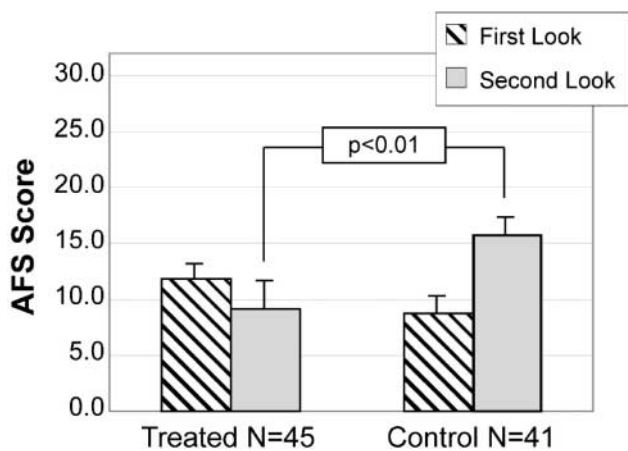


Figure 1. Reduction of American Fertility Society (AFS) adnexal adhesion score with the use of Oxiplex/AP Gel via laparoscopy. Patients undergoing conservative laparoscopic surgery had their adnexa covered with Oxiplex/AP Gel (~ 15 ml) or served as surgery-only control. At the time of second-look laparoscopy 6–10 weeks later, the adnexa coated with Oxiplex/AP Gel ($n = 45$) had a significantly (mean \pm SEM; $P < 0.01$) lower adnexal AFS score compared to control adnexa ($n = 41$).

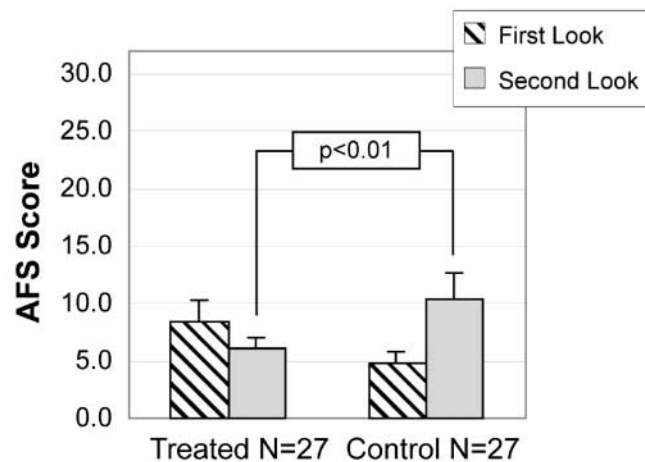
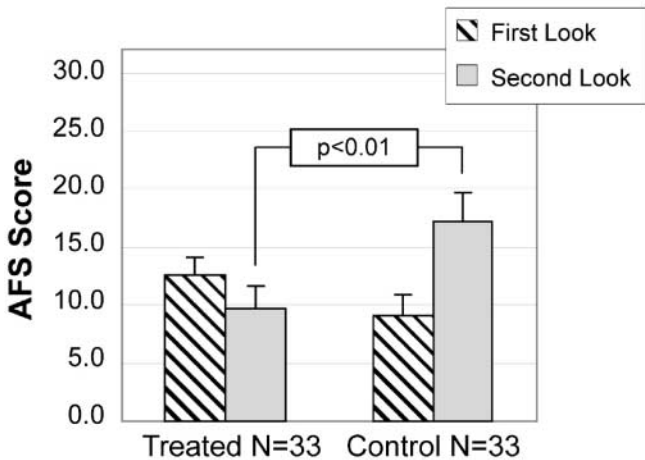
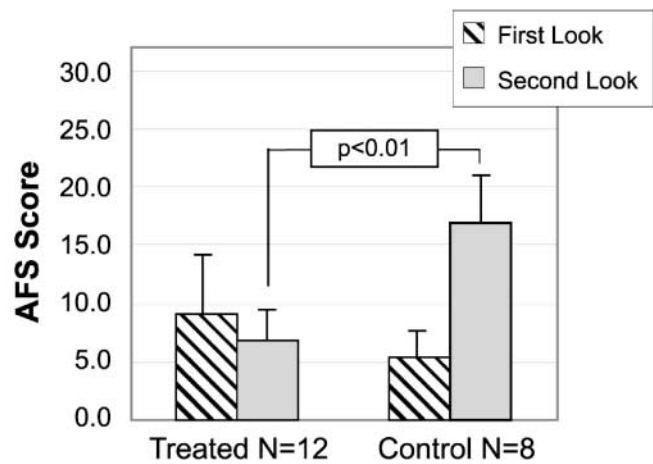


Figure 2. (A) Reduction of American Fertility Society (AFS) adnexal adhesion score in patients without endometriosis. (B, insert) Patients with stage I–IV endometriosis. (C, insert) Patients with stage I–III endometriosis. Adnexa from patients undergoing conservative gynaecological surgery were coated with Oxiplex/AP Gel (~ 15 ml) or served as surgery-only controls. Adnexal AFS adhesion scores were determined at the time of initial surgery as well as at second-look laparoscopy 6–10 weeks later (mean \pm SEM). Adnexa from patients undergoing adhesiolysis only who had no endometriosis (A), patients with AFS stage I–IV endometriosis (B), as well as from those patients with stage I–III endometriosis (excluding stage IV, C) coated with Oxiplex/AP Gel showed a significant improvement in adnexal AFS score compared to controls ($P < 0.01$).

Individual patient benefit can be demonstrated by the number of patients whose adhesion scores shift to a better category of adnexal adhesion score after surgery (Mage *et al.*, 1986; Gomel and Erenus, 1990; Stout *et al.*, 1991; De Bruyne *et al.*, 1997; Nagata *et al.*, 1997a,b; diZerega *et al.*, 2003). An increase in adnexal adhesion score category indicates a worse prognosis for patients. Prognostic categories for minimal (score 0–5), mild (6–10), moderate (11–20), and severe (21–32) scores are provided for each patient group (Table I). In the Oxiplex/AP Gel treatment group, 23 adnexa had a minimal baseline adhesion score (row 1). Of these, 22 remained in the minimal group, one shifted to mild at second look. Review of gel application in this one patient showed that adnexal surgical sites were not covered by gel at the end of surgery. It is not known what the second-look adhesion score would have been if the adnexum had been covered with gel in a manner similar to the other 22 adnexa in this category. In the control population, 23 adnexa were also in the minimal category at the initial surgery. At the time of second look, 13 remained unchanged, 10 had shifted into a higher category: seven mild; one moderate; two severe. These differences in shift analysis are statistically significant ($P < 0.01$).

Five adnexa in the treatment group and four adnexa in the control group had adhesion scores in the mild category at the initial surgery. In the Oxiplex/AP Gel-treated group, two of those had a better adhesion score (minimal) and one a worse score (moderate) at second look. In contrast, in the control group, all four had a worse adhesion category at second look (moderate: three; severe: one). Of the five adnexa that

received Oxiplex/AP Gel in the moderate group at initial surgery, three had a better adhesion score at second look (minimal: two; mild: one) and one had a worse score. In the control group, four of the five adnexa in the moderate category at first surgery had worse adhesion scores at second look (moderate: one; severe: four). Of the Oxiplex/AP Gel-treated adnexa with severe adhesion scores at first look, six had stage IV and two had stage III endometriosis. All of these adnexa remained in the severe category at second look. Of the four adnexa in the severe category that did not have endometriosis, two were in the moderate group and one each in the mild and minimal groups at second look. In the control, nine adnexa were in the severe group at initial surgery. Six of these adnexa had stage IV endometriosis; all six remained in the severe category at second look. Of the three adnexa that were severe at the initial surgery and were not in patients with stage IV endometriosis, only one had a better adhesion score at second look; the other two stayed severe. These changes in the shift table were statistically significant ($P < 0.01$).

The number of individual adnexal adhesion scores (Table II) that improved or stayed the same from first- to second-look laparoscopy versus those that worsened reveals a significant treatment benefit from the use of Oxiplex/AP Gel. Of the adnexa in the Oxiplex/AP Gel group, 87% did not have a worse adhesion score in contrast to 32% of the control adnexa at the time of second look. When individual adnexal adhesion scores are grouped by prognostic category (Table II), the number that improved or stayed the same, from first to second-look laparoscopy versus those that

Table I. Table for shift analysis (Cochran–Mantel–Haenszel statistic)

Baseline American Fertility Society (AFS) category	Total	Second-look AFS scores			
		Minimal (0–5)	Mild (6–10)	Moderate (11–20)	Severe (21–32)
Treatment Surgery + Oxiplex®/AP Gel					
Minimal (0–5)	23	22	1	0	0
Mild (6–10)	5	2	2	1	0
Moderate (11–20)	5	2	1	1	1
Severe (21–32)	12	1	1	2	8
Total	45	27	5	4	9
Control: surgery only					
Minimal (0–5)	23	13	7	1	2
Mild (6–10)	4	0	0	3	1
Moderate (11–20)	5	0	0	1	4
Severe (21–32)	9	0	0	1	8
Total	41	13	7	6	15

Table II. Outcome of clinical trials using the adnexal adhesion score of the American Fertility Society (AFS) as established in 1988

	Individual AFS scores			AFS category		
	Improved or unchanged	Worsened	Total	Improved or unchanged	Worsened	Total
Oxiplex	87% (39)	13% (6)	45	93% (42)	6% (3)	45
Control	32% (13)	68% (28)	41	56% (23)	44% (18)	41

The significant benefit of Oxiplex/AP Gel in reducing adhesions was shown by both a reduction in average AFS score as well as reduction in AFS prognostic category as a result of treatment ($P < 0.01$ for both).

shifted to a worse category, also demonstrates a significant treatment effect of Oxiplex/AP Gel. For example, 93% of the adnexa that received treatment with Oxiplex/AP Gel did not have a worse categorical score. By contrast, 56% of the control adnexa did not have a worse categorical score at the time of second look.

Discussion

The most commonly used adhesion prevention devices either cannot be applied or are difficult to apply during minimally invasive surgery. As a consequence, many surgical procedures still do not utilize adhesion prophylaxis. Oxiplex/AP Gel was developed to specifically address the needs of surgeons performing procedures that result in adhesion formation which often leads to failed surgical therapy (Diamond, 2000; diZerega, 2000). Challenges facing the gynaecological surgeon in placement of an adhesion prevention device include: (i) ease of use; and (ii) retention of the device at the site of application. Oxiplex/AP Gel was specifically developed to address these needs. The carboxymethylcellulose and polyethylene glycol formulation is a transparent, viscoelastic gel that is readily administered to the specific anatomical site(s) where adhesion formation is a concern. This ease of use includes single unit packaging stored at room temperature, which, when opened, delivers the sterile gel and applicator directly to the operating field. The gel viscosity allows the surgeon to control directly the rate of Oxiplex/AP Gel delivery to the surgical site. When the surgeon stops depressing the syringe, gel stops flowing. Gel residing within the applicator tube does not harden, allowing for continued application at the convenience of the surgeon.

Oxiplex/AP Gel was developed by complexing two polymers to maximize tissue adherence. The muco-adherent properties of the gel (Liu and Berg, 2002) allow the device to remain in place even in gravitationally dependent areas such as the anterior abdominal wall after removal of an omental adhesion or the posterior surface of the uterus after myomectomy. A similar formulation of Oxiplex was shown in pre-clinical studies (Oxiplex/SP Gel) to be safe and effective in reducing adhesions to dura following spinal surgery (Rodgers, 2003). Recently, clinical studies showed that patients with severe back pain and lower extremity weakness who had Oxiplex/SP Gel applied over their nerve roots following laminectomy or laminotomy experienced significantly reduced symptoms compared to surgery-only controls (Kim *et al.*, 2003). Here, Oxiplex/AP Gel, specifically designed for use in the peritoneal cavity (Berg *et al.*, 2003) was evaluated in women undergoing conservative gynaecological surgery.

In this clinical study, 49 patients underwent surgical therapy of their adnexa to remove existing adhesions or endometriosis by surgery performed via laparoscopy. Following the primary surgical procedure(s), the treated patients had Oxiplex/AP Gel applied to their adnexa. Oxiplex/AP Gel was applied over the surface of the patient's ovaries, Fallopian tubes, ovarian fossa, and lateral portion of the uterus. With experience, the principle investigators found that a single

layer of gel was sufficient to cover the adnexal surface and adjacent sites. It was not necessary for multiple layers of gel to be applied over an anatomical site. In some cases, when multiple layers of gel were layered over one another, the weight of the excess gel overcame the innate tissue adherence such that gel fell off the surgical site. Typical volume to cover an adnexum was ~15 ml which was administered in ~90 s. Oxiplex/AP Gel was easy to apply to adnexal surfaces including the ovarian fossa and between the ovary and mesosalpinx. This process was facilitated by cessation of vascular oozing after gel coverage.

A single layer of gel was sufficient to protect the tissue during post-surgical repair. The gel was resorbed from the peritoneal cavity prior to the time of second-look laparoscopy, usually within 6 weeks. In four cases, small collections (~5 × 5 mm) of gelatinous material (presumably residual gel) were noted in areas where multiple layers of gel had been applied or in areas deep in the cul-de-sac where intraperitoneal clearance may have been effected (Ahrenholz and Simmons, 1988; diZerega and Rodgers, 1992) particularly in cases of grade IV endometriosis. In two instances, biopsies of these sites were consistent with residual gel. There did not appear to be any clinical significance of the residual gel: residuum did not interconnect tissue surfaces; was not associated with adhesions; did not obstruct organ mobility. Although it is reassuring to see gel persisting at the site of application, avoidance of applying excess gel is recommended.

Adhesion reduction

Due to the study requirements for laparoscopy, many patients had no or minimal adnexal adhesions at the time of their initial surgery. All of the adnexa with no adhesions at the time of initial surgery had endometriomas. Twenty-two out of 23 of the Oxiplex/AP-treated adnexa continued to have minimal adhesion scores at second-look laparoscopy. By contrast, only 13/23 control adnexa with minimal adhesion scores were unchanged at the time of second look. At the time of second-look laparoscopy, 2/45 of the Oxiplex/AP Gel-treated adnexa demonstrated substantial adhesion formation progressing to moderate or severe adhesion category; by contrast, 11/41 control adnexa shifted into the moderate or severe category. Both of these differences are statistically significant. In this study, three of 45 treated adnexa had a change or shift in their adhesion score toward a higher or worse category. By contrast, 18 of 41 control adnexa had a shift in their adhesion score into a worse prognostic category at second-look laparoscopy ($P < 0.001$). This reduction in post-operative adnexal adhesions demonstrates a clinically significant benefit of Oxiplex/AP Gel as categorical reduction in adnexal adhesions has been associated with better clinical outcomes (Gomel and Erenus, 1990; Stout *et al.*, 1991; De Bruyne *et al.*, 1997; Nagata *et al.*, 1997a,b; Mage *et al.*, 2000; diZerega *et al.*, 2003). This is the first demonstration of a site-specific adhesion prevention device that can be easily and quickly applied to the adnexa including the ovarian fossa and between the ovary and mesosalpinx, and that significantly reduces adhesions to the ovary and Fallopian

tube following surgical therapy of the adnexa by laparoscopy.

Adhesion scoring systems were developed to help establish correlations between adhesions and disease outcomes to guide in management. Adhesion scoring is not only used for prognosis, but it can also be a determinant of therapy (Mage *et al.*, 2000). The most widely used system is the one proposed as the Adnexal Adhesion Classification of the AFS (1988). Clinical correlations using the AFS Adnexal Adhesion Classification have been previously summarized (diZerega *et al.*, 2003). In general, patients with minimal adhesion scores do well; in contrast those with severe adhesion scores do poorly. Recently, the US Food and Drug Administration recommended that the AFS Adnexal Adhesion Classification be used as a clinical outcome measure in clinical studies of devices intended to reduce post-surgical adhesion formation (Guidance for Industry (2002)).

Limitations

Oxiplex/AP Gel did not appear to provide protection from adhesion formation in all clinical situations. Patients with severe adhesion scores at the initial laparoscopy and concurrent stage IV endometriosis did not have a reduction in adhesion score even with the use of Oxiplex/AP Gel. In situations where residual disease persists beyond the time Oxiplex/AP Gel is resorbed from the surgical site, as may occur with residual endometriosis left deep in the cul-de-sac (stage IV disease), the development of adhesions would be expected (Nisolle and Donnez, 1997). In this study when the patients had a severe adhesion score at the time of initial laparoscopy in the absence of endometriosis, presumably from prior surgery or previous infection, three out of three patients who received Oxiplex/AP Gel had an improvement in adhesion score to the moderate category at the time of second-look laparoscopy. There are no data available in the literature indicating that patients with a moderate adnexal adhesion score derive a clinical benefit different from those that have a score in the severe category. Some suggestion of benefit due to ease of oocyte retrieval at the time of IVF was reported by Nagata *et al.* (1998).

At present, Oxiplex/AP Gel seems well suited to address the need for general adhesion prophylaxis in peritoneal cavity surgery. However, clinical needs remain. Patients with intra-peritoneal infections as well as those with severe endometriosis represent remaining challenges to devise technologies. Strategies combining pharmaceuticals with devices to provide prolonged, physiological effects at the site of potential adhesion formation appear promising.

In summary, the use of Oxiplex/AP Gel in this multicentre evaluation showed a significant reduction in the number of adnexa that developed adhesions following surgery. In the Oxiplex/AP Gel-treated group, 93% of the adnexa did not have a worse adhesion category in contrast to 56% of the control adnexa at the time of second look. These differences are highly significant and demonstrate the overall benefit of Oxiplex/AP Gel when used together with good surgical technique to enhance the likelihood of a good response to

surgical therapy. The gel was safe and no complications or adverse events were observed in the treatment group. A specially designed applicator facilitated rapid coating of anatomical sites where clinical concern of adhesion formation was directed. Although confirmation of these data awaits additional clinical studies, the use of Oxiplex/AP Gel appears to provide a unique benefit to patients undergoing gynaecological surgery. Additional clinical trials are currently underway.

Acknowledgements

We thank Trish Lyons for her editorial assistance in the preparation of this article. Support for this study was provided in part by FzioMed, Inc., San Luis Obispo, California, USA.

References

- Ahrenholz DH and Simmons RL (1988) Peritonitis and other intra-abdominal infections. In Howard RJ and Simmons RL (eds) *Surgical Infectious Disease*, 2nd edn. Appleton & Lange, East Norwalk, CT, pp. 624, Fig 29–28.
- Almeida OD Jr and Val-Gallas JM (1997) Conscious pain mapping. *J Am Assoc Synecol Laparosc* 4,587–590.
- American Fertility Society (1988) The American Fertility Society classifications of adnexal adhesions, anomalies and intrauterine adhesions, distal tubal occlusion, tubal occlusion secondary to tubal ligation, tubal pregnancies, Mullerian anomalies and intrauterine adhesions. *Fertil Steril*, 49,949.
- Becker JM, Dayton MT, Fazio VW, Beck DE, Stryker SJ, Wexner SD *et al.* (1996) Prevention of postoperative adhesions by a sodium hyaluronate based bioresorbable membrane: a prospective, randomized double-blind multicenter study. *J Am Coll Surg* 183,297–306.
- Berg RA, Rodgers KE, Cortese S, Espinoza T, Roda N and diZerega GS (2003) Post-surgical adhesion reformation is inhibited by Oxiplex adhesion barrier gel. In Marana R, Busacca M, and Zupi E (eds) *International Proceedings. World Meeting on Minimally Invasive Surgery in Gynecology*, Rome, pp. 17–21.
- Canis M, Botchorishvili R, Tambiuro S *et al.* (2001) Adhesion prevention in the surgical treatment of pelvic endometriosis. *Gynecol Endosc* 10, 99–106.
- De Bruyne F, Hucke J and Willers R (1997) The prognostic value of salpingoscopy. *Hum Reprod* 12,266.
- Diamond MP (1996) Reduction of adhesions after uterine myomectomy by Seprafilm (HAL-F): a blinded, prospective, randomized, multicenter clinical study. *Seprafilm Adhesion Study Group. Fertil Steril* 66,904–910.
- Diamond MP (2000) Incidence of postsurgical adhesions. In diZerega GS (ed.) *Peritoneal Surgery*. Springer-Verlag, New York, pp. 217–220.
- Diamond MP, Luciano A, Johns DA, Dunn R, Young P and Bieber E (2003) Reduction of postoperative adhesions by N,O-carboxymethylchitosan: a pilot study. *Fertil Steril* 80,631–636.
- diZerega GS (2000) Peritoneum, peritoneal healing, and adhesion formation. In diZerega GS (ed.) *Peritoneal Surgery*. Springer-Verlag, New York, pp. 3–37.
- diZerega GS and Rodgers KE (1992) *The Peritoneum*. Springer-Verlag, New York, 33 pp.
- diZerega GS, Vercos SJS, Young P, Kettle M, Kobak W, Martin D, Sanfilippo J, Peers EM, Scrimgeour A and Brown CB (2002) A randomised, controlled pilot study of the safety and efficacy of 4% icodextrin solution (Adept™) in the reduction of adhesions following laparoscopic gynaecological surgery. *Hum Reprod* 17,1031–1038.
- diZerega GS, Roth R and Johns DB (2003) Quantitation of peritoneal adhesions and correlation with clinical outcomes. *Infertil Reprod Med Clin N Am* 14,431–456.
- Gomel V and Erenus M (1990) Prognostic value of the American Fertility Society's (AFS) classification for distal tubal occlusion (DTO) [meeting abstract]. *Fertil Steril* 64 (Suppl 1),P-097,S106.
- Guidance for Industry (2002) *Guidance for resorbable adhesion barrier devices for use in abdominal and/or pelvic surgery*. DHHS/FDA.
- Howard FM, El-Minawi AM and Sanchez RA (2000) Conscious pain mapping by laparoscopy in women with chronic pelvic pain. *Obstet Gynecol* 96,934–939.

- Interceed (TC7) Adhesion Barrier Study Group (1993) Microsurgery alone or with Interceed absorbable adhesion barrier for pelvic sidewall adhesion reformation. *Surg Gynecol Obstet* 177,135–139.
- Johns DB, Keyport GM, Hoehler F and diZerega GS (2001a) Intergel adhesions prevention study group: reduction of postsurgical adhesions with intergel adhesion prevention solution. A multicenter study of safety and efficacy after conservative gynecologic surgery. *Fertil Steril* 76,595–604.
- Johns DB, Keyport GM, Hoehler F *et al.* (2001b) Adhesion Prevention Study Group. Reduction of postsurgical adhesions with Intergel adhesion prevention solution: a multicenter study of safety and efficacy after conservative gynecologic surgery. *Fertil Steril* 76,595–604.
- Kim KD, Wang JC, Robertson DP, Brodke DS, Olson EM, Duberg AC, BenDebba M, Block K and diZerega GS (2003) Reduction of radiculopathy and pain with Oxiplex/SP Gel after laminectomy, laminotomy, and discectomy. *Spine* 28,1080–1087.
- Liu LS and Berg RA (2002) Adhesion barriers of carboxymethyl cellulose and polyethylene oxide composite gels. *J Biomed Mater Res* 63,326–332.
- Lower AM, Hawthorn RJS, Ellis H, O'Brien F, Buchan S and Crowe AM (2000) The impact of adhesions on hospital readmissions over ten years after 8849 open gynaecological operations: an assessment from the Surgical and Clinical Adhesions Research Study. *Br J Obstet Gynecol* 107,855–862.
- Lundorff P, vanGeldopr H, Tronstad SE *et al.* (2001) Reduction of postsurgical adhesions with ferric hyaluronate gel: a European Study. *Hum Reprod* 16,1982–1988.
- Mage G, Pouly JL, de Joliniere JB *et al.* (1986) A preoperative classification to predict the intrauterine and ectopic pregnancy rates after distal tubal microsurgery. *Fertil Steril* 46,807–810.
- Mage G, Wattiez A, Canis M, Pouly JL, Alexandre F and Bruhat M (2000) Classification of adhesion. In diZerega GS (ed.) *Peritoneal Surgery*. Springer-Verlag, New York, pp. 221–228.
- Marana R and Muzii L (2000) Infertility and adhesions. In diZerega GS (ed.) *Peritoneal Surgery*. Springer-Verlag, New York, pp. 329–333.
- Menzies D and Ellis H (1990) Intestinal obstruction from adhesions-how big is the problem? *Ann R Coll Surg, Engl* 72,60–63.
- Mettler L, Audebert A, Lehmann-Willenbrock E, Jacobs VR and Schive K (2003) New adhesion prevention concept in gynecological surgery. *JSLs* 7,207–209.
- Nagata Y, Honjou K, Shindou M *et al.* (1997a) Effects of periovarian adhesions on the results of IVF-ET treatment. *J Fertil Implant (Tokyo)* 14, 54–57.
- Nagata Y, Honjou K, Shindou M *et al.* (1997b) Alternate prognostic classification for adnexal adhesions divided into peritubal adhesions and periovarian adhesion; severe periovarian adhesions were the major cause of infertility [abstract]. *Fertil Steril* 68,P090–S135.
- Nagata Y, Honjou K, Sonada M *et al.* (1998) Periovarian adhesions interfere with the diffusion of gonadotropin into the follicular fluid. *Hum Reprod* 13,2072–2076.
- Nisolle M and Donnez J (1997) Peritoneal endometriosis, ovarian endometriosis, and adenomyotic nodules of the rectovaginal septum are three different entities. *Fertil Steril* 68,585–596.
- Onders RP and Mittendorf EA (2003) Utility of laparoscopy in chronic abdominal pain. *Central Surgical Assoc, 60th Annual Meeting. Surgery*, 549–554.
- Ray NF, Larsen JW, Stillman RJ and Jacobs RJ (1993) Economic impact of hospitalizations for lower abdominal adhesiolysis in the United States in 1988. *Surg Gynecol Obstet* 176,271–276.
- Rodgers KE, Robertson JT, Espinoza T, Oppelt W, Cortese S, diZerega GS and Berg RA (2003) Reduction of epidural fibrosis in lumbar surgery with Oxiplex adhesion barriers of carboxymethylcellulose and polyethylene oxide. *Spine J* 3,277–284.
- Rosen DMB and Sutton CJG (2000) Outcome measures and adhesion formation: pain and postsurgical adhesion. In diZerega GS (ed.) *Peritoneal Surgery*. Springer-Verlag, New York, pp. 321–327.
- Schwartz H and Blackmore JM (2000) Bioresorbable compositions of carboxy polysaccharide polyether intermolecular complexes and methods for their use in reducing surgical adhesions. *US Patent* 6,017–301.
- Stout AL, Steege JF, Dodson WC *et al.* (1991) Relationship of laparoscopic findings to self-report of pelvic pain. *Am J Obstet Gynecol*,164–173.
- Surgical Membrane Study Group (1992) Prophylaxis of pelvic side wall adhesion formation with Gore-Tex surgical membrane: a multicenter clinical investigation. *Fertil Steril* 57,921–923.
- Tulandi T (2001) Introduction-prevention of adhesion formation: the journey continues. *Hum Reprod Update* 7,545–546.

Submitted on August 8, 2004; resubmitted on September 20, 2004; accepted on October 26, 2004